

# Correlation Between Hump Dimensions and Curve Severity in Idiopathic Scoliosis Before and After Conservative Treatment

Angelo Gabriele Aulisa, MD,\* Vincenzo Guzzanti, MD,\*<sup>§</sup> Carlo Perisano, MD,<sup>†</sup>  
Emanuele Marzetti, MD, PhD,<sup>†,‡</sup> Amerigo Menghi, MD,<sup>†</sup> Marco Giordano, MD,\* and Lorenzo Aulisa, MD<sup>†</sup>

**Study Design.** Prospective study in 150 consecutive outpatients affected by adolescent idiopathic scoliosis (AIS).

**Objectives.** The purposes were to (1) identify a correlation between hump dimensions and the severity of scoliotic curve, and (2) evaluate how the treatment influenced the main parameters of scoliosis.

**Summary of Background Data.** The existence of a relationship between clinical deformities and curve severity in AIS is still debated. Furthermore, only a few studies have investigated the effectiveness of conservative treatment for idiopathic scoliosis taking into account both clinical and radiologic factors.

**Methods.** 150 consecutive outpatients (mean age  $12.8 \pm 1.9$  years) affected by AIS were subjected to conservative brace-based treatment. 134 participants completed the treatment protocol. Two parameters were considered to evaluate the treatment progress: the hump and the Cobb angle. Measurements were determined at the beginning and the end of treatment. Statistical analyses were performed in the whole sample and after dividing the study participants into 4 subgroups:

patients with lumbar ( $n=66$ ) or thoracic curves ( $n=68$ ), patients ranging in age between 6 and 13 years ( $n=89$ ) and patients  $\geq 14$  years of age ( $n=45$ ).

**Results.** A positive correlation was detected between the hump dimension and curve severity at the beginning and the end of treatment, except for lumbar curves at baseline. The deformity was effectively corrected by the orthotic treatment (Cobb angle:  $29.4 \pm 8.5^\circ$  at baseline and  $19.3 \pm 9.8^\circ$  at the end of treatment; hump severity:  $11.6 \pm 5.6$  mm at baseline and  $6.2 \pm 4.6$  mm at the end). In addition, our data indicate that the hump correction is more evident than that of the curve registered in Cobb degrees.

**Conclusion.** A significant correlation exists between the hump dimension and curve severity both at the beginning and the end of treatment, except for lumbar curves at baseline. The brace treatment confirmed its effectiveness in arresting the deformity progression and inducing a remodeling both of the scoliotic curve and the hump.

**Key words:** conservative treatment, hump, idiopathic scoliosis, scoliosis curve.

**Spine 2018;43:114–119**

From the \*Department of Orthopaedics and Traumatology, Children's Hospital Bambino Gesù, Institute of Scientific Research, P.zza S. Onofrio 4 – 00165 Rome, Italy; <sup>†</sup>Department of Orthopaedics, Catholic University of the Sacred Heart, University Hospital "Agostino Gemelli", L.go F. Vito, 1 – 00168 Rome, Italy; <sup>‡</sup>Department of Aging and Geriatric Research, Institute on Aging, Division of Biology of Aging, University of Florida, Gainesville, FL 32610–0143, USA; and <sup>§</sup>University of Cassino, Strada Folcare, 4 – 03043 Cassino (FR), Italy.

Acknowledgment date: April 28, 2010. First revision date: June 7, 2010. Acceptance date: June 14, 2010.

The manuscript submitted does not contain information about medical device(s)/drug(s).

No funds were received in support of this work. No benefits in any form have been or will be received from a commercial party related directly or indirectly to the subject of this manuscript.

Angelo Gabriele Aulisa, Vincenzo Guzzanti, Carlo Perisano, Emanuele Marzetti, Amerigo Menghi, Marco Giordano and Lorenzo Aulisa, These authors contributed equally to this work.

Address correspondence and reprint requests to Angelo Gabriele Aulisa, MD, P.zza S. Onofrio 4 – 00165 Rome, Italy; E-mail: agaulisa@tiscali.it

DOI: 10.1097/BRS.0b013e3181ee77f9

114 www.spinejournal.com

Copyright © 2017 Wolters Kluwer Health, Inc. Unauthorized reproduction of this article is prohibited.

Structured scoliosis is a permanent, progressive deformity not susceptible of improvement without external events. Scoliosis produces a series of intrinsic (discs and vertebrae) and extrinsic (thoracic cage, spine muscles, capsules and ligaments, bone marrow and spinal roots, diaphragm and thoraco-abdominal viscera) deformities, causing significant esthetic damage and respiratory function impairment.<sup>1–4</sup> The hump is the most evident clinical sign of scoliosis and also represents an important prognostic factor in terms of curve progression.<sup>5</sup> However, many studies have questioned the existence of a correlation between the clinical deformity and the curve severity evaluated by radiograph.<sup>6–15</sup> Even though a significant correlation between clinical deformities and radiologic measurements exists, the variability may be so high that it is impossible to predict the curve degree based on clinical parameters.<sup>6</sup> Indeed, except for the early stages of scoliosis development,

the clinical deformity is considered to be more evident than the Cobb angle.<sup>6</sup> Furthermore, it has been reported that the rib hump and depression are not directly related to any standard radiographic measurements.<sup>7</sup> In addition, a weak correlation has been observed between Cobb degrees and the hump measured via surface topography.<sup>8,16</sup>

However, in several Italian studies emerged that the hump, measured by a hump-meter, was significant for a threshold of 5 mm.<sup>17–20</sup> Moreover, a trunk rotation angle  $\geq 7^\circ$  for thoracic and right convex curves and  $\geq 6^\circ$  for thoracolumbar, lumbar and left convex curves is considered a reliable criterion to identify patients with Cobb angles of  $25^\circ$  or greater, thus reducing the need for spinal radiography.<sup>21</sup>

With regards to the therapeutic approach to scoliosis, the effectiveness of the brace treatment is still debated. In fact, in some studies bracing did not reduce the need for surgery.<sup>22,23</sup> In contrast, other investigators reported that the brace treatment was able to prevent surgery and arrest the progression of deformities.<sup>24</sup>

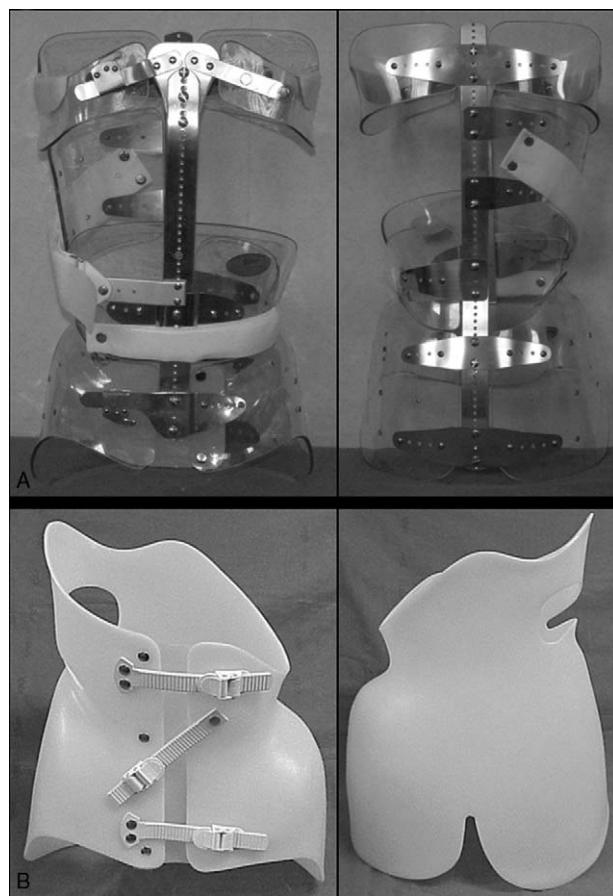
However, only a few studies have investigated the effectiveness of conservative treatment for idiopathic scoliosis taking into account both clinical and radiologic factors. In addition, no studies have explored the possibility that conservative treatment may differentially affect clinical and radiologic parameters.

Although a close relationship between Cobb degrees and clinical parameters describing the deformity appears logical and is generally accepted, discrepancies between those two factors have been reported. For instance, Weiss<sup>25</sup> described a case in which esthetic improvement was achieved in spite of a curve worsening (in Cobb degrees). In contrast, Rigo<sup>26</sup> reported a case with a pretreatment curve  $>50^\circ$ , in which, after brace treatment, a concomitant improvement in Cobb angle and esthetic appearance was attained. Finally, bracing reduced rotational deformities in scoliotic adolescent girls compared to age-matched, untreated controls, while stabilizing radiologic parameters.<sup>27</sup>

Based on these premises, the present study sought to (1) verify the existence of a correlation between hump dimensions and the severity of scoliosis curve (2); determine the effectiveness of the brace treatment in terms of both hump dimension and curve severity (3); identify the existence of a correlation between the hump correction and the scoliotic curve, in order to determine whether the hump correction prevails over that of the curve.

## MATERIALS AND METHODS

We conducted a prospective study in 150 consecutive outpatients affected by adolescent idiopathic scoliosis (AIS). One-hundred thirty-four patients (13 males and 121 females) carried out the treatment until complete skeleton maturity. Four of the sixteen patients who have abandoned the treatment, before the end of the growth, required surgery. For each participant, informed consent was obtained from his/her parents. Inclusion criteria were: presence of



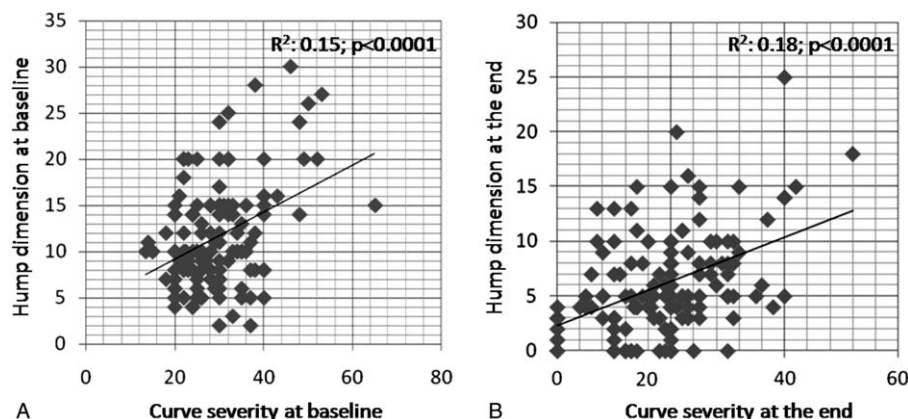
**Figure 1.** Lyon brace (A) and P.A.S.B. brace (B).

progressive adolescent idiopathic scoliosis; growing age; absence of radiographic signs of congenital or other deformities at the clinical examination; absence of other spine pathologies. The brace model was prescribed according to the curve type: Lyon brace in 79 patients, progressive action short brace (PASB) in 42 patients, and a mixed treatment with PASB + Lyon brace in the remaining 13 participants (Figure 1A, B).

Two parameters were considered for the evaluation of treatment effectiveness: the hump, measured by a hump-meter, and the Cobb angle, determined by standing radiograph. Measurements were obtained at the beginning and the end of treatment by 3 independent operators.

## Statistics

Statistical analyses were performed using the SPSS for Windows 13.0 software. All tests were two-sided; differences were considered significant at  $P < 0.05$ . Differences before and after treatment were assessed by paired-wise *t* tests. Linear regression analysis was employed to explore correlations among variables. Analyses were performed in the whole patient population and after dividing the study sample into 4 subgroups (1): patients with lumbar ( $n = 66$ ) or (2) thoracic curves ( $n = 68$ ), (3) patients ranging in age between 6 and 13 years ( $n = 89$ ), and (4) patients  $\geq 14$  years



**Figure 2.** Correlations between the hump dimension and the curve severity at baseline (A) and the end of treatment (B).

of age (n=45). All data are presented as mean values ± SEM.

**RESULTS**

The mean age of participants at baseline was 12.8 ± 0.2 years. A significant correlation between hump dimensions and the curve severity was detected both at the beginning (Figure 2A) and the end of treatment (Figure 2B). Similar results were obtained in subgroup analyses (Table 1; Figure 3A–H), except that no significant correlation was found at baseline between the hump dimension and curve severity in patients with lumbar curves (Figure 3C). Our analyses also revealed that the hump correction was more evident than the curve correction in Cobb degrees (P=0.011; data not shown), except for lumbar curves and patients aged ≤ 13 years (data not shown). The curve severity at the beginning of treatment was 29.41 ± 0.74 Cobb degrees, whereas the hump dimension was 11.61 ± 0.48 mm. The mean duration of treatment was 4.9 ± 0.2 years. Overall, a ~10° Cobb correction was obtained, corresponding to ~5.4 mm hump reduction (Figure 4A,B). Nobody of the 134 cases have been a

progression of the curve ≥ 5° Cobb, although between these there was a patient with a curve of 53° Cobb, that had refused the surgery

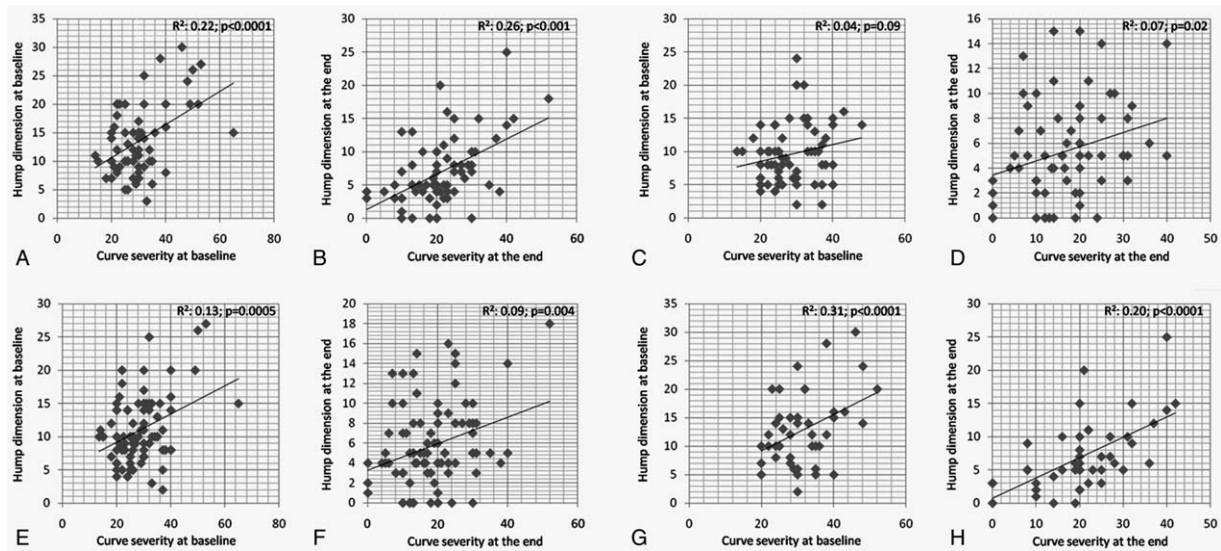
**DISCUSSION**

Our results indicate that a significant correlation exists between the hump dimension and curve severity in patients affected by AIS. This correlation was evident both at baseline and after treatment completion. However, no significant correlation between the hump dimension and curve severity was evident in patients with lumbar curve at baseline. Furthermore, our results support the effectiveness of the brace treatment for AIS regardless of the patient age and curve type. Finally, our data indicate that the hump correction is more evident than the curve improvement, with the exception of lumbar curves and the younger group. The smaller hump correction relative to the curve in patients aged ≤ 13 years may be the expression of their higher residual growth, which may contribute to a favorable remodeling of the deformity at this younger age.

Although the existence of a correlation between the clinical deformity and curve severity appears logical, the

<b>TABLE 1. Hump Dimensions (mm) and Curve Severity (Cobb Degrees) According to the Curve Type and Age</b>			
	<b>Baseline</b>	<b>End of treatment</b>	<b>p</b>
<i>Patients with thoracic curves</i>			
Hump dimension (mm)	13.57 ± 0.72	6.96 ± 0.62	<0.0001
Curve severity (Cobb degrees)	30.31 ± 1.16	21.22 ± 1.19	<0.0001
<i>Patients with lumbar curves</i>			
Hump dimension (mm)	9.59 ± 0.54	5.39 ± 0.49	<0.0001
Curve severity (Cobb degrees)	28.48 ± 0.90	17.30 ± 1.18	<0.0001
<i>Age ≤ 13 years</i>			
Hump dimension (mm)	10.97 ± 0.54	5.72 ± 0.44	<0.0001
Curve severity (Cobb degrees)	28.38 ± 0.92	18.51 ± 1.02	<0.0001
<i>Age ≥ 14 years</i>			
Hump dimension (mm)	11.70 ± 0.60	6.17 ± 0.49	<0.0001
Curve severity (Cobb degrees)	30.05 ± 0.91	19.80 ± 1.03	<0.0001



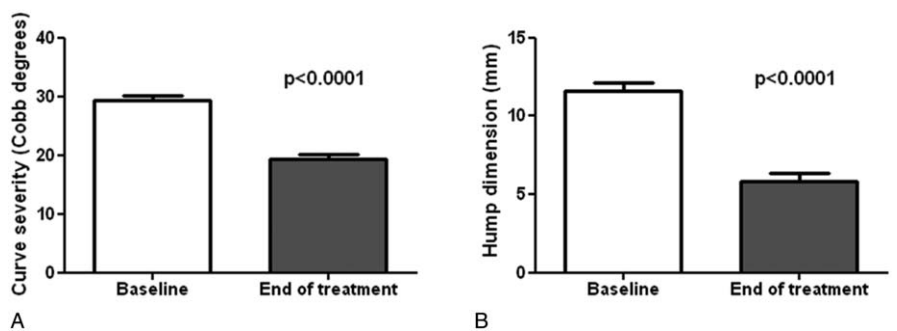


**Figure 3.** Correlations between the hump dimension and the curve severity at baseline and the end of treatment in patients with thoracic (A, B) or lumbar curves (C, D) and in participants aged  $\leq 13$  (E, F) or  $\geq 14$  years (G, H).

hump is considered to be more evident than the Cobb angle.<sup>6</sup> In addition, it is proposed that the rib hump and depression are not correlated with any standard radiographic measurements.<sup>7</sup> Moreover, a weak correlation has been reported between Cobb degrees and the hump measured via surface topography.<sup>8,16</sup> Notwithstanding, other investigators showed that the angle of trunk rotation may identify certain types of scoliotic curves.<sup>21</sup> Furthermore, Duval-Beaupere<sup>28</sup> reported that the rib hump of thoracic and thoracolumbar curves may be predictive of curve progression in patients with scoliotic angle  $< 30^\circ$ .

These mixed results may be the expression of the lack of consensus regarding methods used to quantify morphologic and radiographic parameters of scoliosis. Indeed, several techniques have been proposed to quantitatively assess scoliosis for screening and follow-up purposes. However, there are not widely-accepted objective criteria for the screening tools currently available. It has been suggested that a scoliometer reading higher than  $7^\circ$ , a rib bump greater than 10 mm, and

2+ fringe difference at the Moirè topography may identify individuals affected by scoliosis.<sup>29-33</sup> Interestingly, all scoliosis cases amenable to treatment may be ascertained by the rib deformity at 10 years of age.<sup>6</sup> In addition, the integrated shape-imaging system (ISIS) has proven effective in predicting the curve evolution in over 80% of patients.<sup>34</sup> The back surface topography is able to identify the presence, level and side of the scoliotic curve; however, the amplitude of scoliosis cannot be accurately determined.<sup>35</sup> Furthermore, growth has a significant impact on the relationship between the rib cage and the spinal deformity. Indeed, the correlation between the thoracic surface and the hump is weak in very young girls and becomes stronger with growth.<sup>9</sup> Other non-invasive clinical measurements, such as the hump height, the trunk axial rotation and the distance between processus spinosus and the plumb line, have shown a weak correlations with radiographic values.<sup>15</sup> Results from the present study support the usefulness of the hump-meter for the clinical assessment of scoliotic curves. Indeed, the hump-meter has



**Figure 4.** Curve severity (Cobb degrees) and hump dimensions (mm) at the beginning (A) and the end of treatment (B) in the whole study sample.

been previously proposed as a reliable and inexpensive tool for the screening, diagnosis and evaluation of the curve during brace treatment of scoliosis.<sup>17-20</sup> Moreover, the use of this tool reduces the need for radiographies, therefore decreasing the exposure to radiations in the growing age. It is possible that a larger case series could have allowed us to determine a formula to calculate the Cobb degrees from the values obtained by the hump-meter, according to what previously proposed by Bunnell for the scoliometer.<sup>11,13</sup>

Our study also demonstrates the effectiveness of the brace treatment for AIS. Indeed, controversies exist with regards to the efficacy of conservative treatment in patients affected by AIS. Some studies have suggested that bracing may represent an effective strategy to treat AIS, owing to its ability of halting scoliosis progression, thus reducing the need for surgery.<sup>24,36-43</sup> However, these encouraging results have not been confirmed by others.<sup>22,23,44,45</sup> Nevertheless, in our case series, the PASB and the Lyon brace impeded the evolution process and induced a remodeling both of the scoliotic curve (Figure 2) and the hump via corrective forces and load redistribution.<sup>24,46-49</sup> Furthermore, our group has recently shown that the PASB is highly effective in correcting thoracolumbar curves in AIS patients, maintaining its efficacy over the long-term.<sup>36</sup> This is witnessed by the fact surgical correction was not needed in any PASB-treated patients. Therefore, the brace-treatment is able to produce remarkable esthetic improvements, with positive impact on treatment compliance. In fact, as observed by Mehta,<sup>50</sup> the body deformity is what patients care the most. Physicians' greatest concern is often the radiographic deformity, but what patients wish is to abolish the esthetic deformity and the associated psychological discomfort.

## ➤ Key Points

- ❑ Our results indicate that a significant correlation exists between the hump dimension and curve severity in patients affected by AIS.
- ❑ Finally, our data indicate that the hump correction is more evident than the curve improvement, with the exception of lumbar curves and the younger group.
- ❑ Nevertheless, in our case series, the PASB and the Lyon brace impeded the evolution process and induced a remodeling both of the scoliotic curve (Figures 12) and the hump via corrective forces and load redistribution.<sup>24,46-49</sup>
- ❑ Therefore, the brace-treatment is able to produce remarkable esthetic improvements, with positive impact on treatment compliance.

## References

1. Giordano A, Aulisa L, Landucci B, Galli M, Pistelli R, Fuso L, Galli G. Evaluation of Ventilation and Diaphragm Movement (DM) in Idiopathic Scoliosis (Iscol) by Radioaerosol lung Scintigraphy (RLS). *Europ Journ of Nuclear Medic* 1989;15:392.
2. Giordano A, Di Fazio P, Aulisa L, Galli M, Pistelli R, Fuso L, Galli M. Evaluation of Diaphragm movement: A useful adjunct to ventilation scan. *J Nucl Med Allied Sci* 1990;34:184-6.
3. Padua R, Ceccarelli E, Pitta L, De Santis V, Aulisa L. Radioaerosol lung scintigraphy in idiopathic scoliosis. *Stud Health Technol Inform* 2002;88:279-84.
4. Padua S, Aulisa L, Fieri C, Ciappi G, Di Marzo A. Valutazione dei valori polmonari in scoliosi idiopatiche dorsali e rapporti con la rotazione vertebrale prima e dopo l'intervento di artrodesi. *Prog in Pat Vert* 1979;II:81-91.
5. Duval-Beaupere G. Threshold values for supine and standing Cobb angles and rib hump measurements: prognostic factors for scoliosis. *Eur Spine J* 1996;5:79-84.
6. Bunnell WP. Selective screening for scoliosis. *Clin Orthop Relat Res* 2005;(434):40-5.
7. Thulbourne T, Gillespie R. The rib hump in idiopathic scoliosis. Measurement, analysis and response to treatment. *J Bone Joint Surg Br* 1976;58:64-71.
8. Goldberg CJ, Kalisz M, Moore DP, Fogarty EE, Dowling FE. Surface topography, Cobb angles, and cosmetic change in scoliosis. *Spine (Phila Pa 1976)* 2001;26:E55-63.
9. Grivas TB, Vasiliadis ES, Mihas C, Savvidou O. The effect of growth on the correlation between the spinal and rib cage deformity: implications on idiopathic scoliosis pathogenesis. *Scoliosis* 2007;14:11.
10. Burwell RG, James NJ, Johnson F, Webb JK, Wilson YG. Standardised trunk asymmetry scores. A study of back contour in healthy school children. *J Bone Joint Surg Br* 1983;65:452-63.
11. Korovessis PG, Stamatakis MV. Prediction of scoliotic Cobb angle with the use of scoliometer. *Spine (Phila Pa 1976)* 1996;21:1661-6.
12. Theologis TN, Fairbank JC, Turner-Smith AR, Pantazopoulos T. Early detection of progression in adolescent idiopathic scoliosis by measurement of changes in back shape with the Integrated Shape Imaging System scanner. *Spine (Phila Pa 1976)* 1997;22:1223-7; discussion 1228.
13. Sappas G, Papagelopoulos PJ, Kateros K, Koundis GL, Boscainos PJ, Koukou UI, Katonis P. Prediction of Cobb angle in idiopathic adolescent scoliosis. *Clin Orthop Relat Res* 2003;(411):32-9.
14. Denton TE, Randall FM, Deinlein DA. The use of instant moiré photographs to reduce exposure from scoliosis radiographs. *Spine (Phila Pa 1976)* 1992;17:509-12.
15. Grosso C, Negrini S, Boniolo A, Negrini AA. The validity of clinical examination in adolescent spinal deformities. *Stud Health Technol Inform* 2002;91:123-5.
16. Sakka S, Mehta MH. Correlation of the Quantec scanner measurements with x-ray measurements in scoliosis. *J Bone Joint Surg Br* 1996;78-B (suppl I):57.
17. Merolli A, Padua R, Pitta L, Aulisa AG, Ceccarelli E, Aulisa L. A statistical analysis of the familial incidence of idiopathic scoliosis. *Stud Health Technol Inform* 2002;88:37.
18. Aulisa L, Bartolini F, Tamburelli F, Valassina A. La diagnosi precoce della scoliosi: il problema del metodo. *Arch Putti* 1982;32:129-37.
19. Grosso C, Paroli C, Cabitza P, Negrini S. Ripetibilità e accuratezza della rotazione assiale del tronco e dell'altezza del gibbo: uno studio clinico. *Giornale Italiano di Medicina Riabilitativa* 2002;8:65-6.
20. Ferraro C, Gottardo A. La misurazione del gibbo: studio critico mediante un dispositivo tascabile. *Minerva Ortopedica e Traumatologica* 1993;44:637-43.
21. Samuelsson L, Noren L. Trunk rotation in scoliosis: the influence of curve type and direction in 150 children. *Acta Orthop Scand* 1997;68:273-6.
22. Goldberg CJ, Dowling FE, Hall JE, Emans JB. A statistical comparison between natural history of idiopathic scoliosis and brace treatment in skeletally immature adolescent girls. *Spine (Phila Pa 1976)* 1993;18:902-8.
23. Goldberg CJ, Moore DP, Fogarty EE, Dowling FE. Adolescent idiopathic scoliosis: the effect of brace treatment on the incidence of surgery. *Spine (Phila Pa 1976)* 2001;26:42-7.

24. Nachemson AL, Peterson LE. Effectiveness of treatment with a brace in girls who have adolescent idiopathic scoliosis. A prospective, controlled study based on data from the Brace Study of the Scoliosis Research Society. *J Bone Joint Surg Am* 1995;77:815–22.
25. Weiss HR. Clinical improvement and radiological progression in a girl with early onset scoliosis (EOS) treated conservatively—a case report. *Scoliosis* 2006;1:13.
26. Rigo M. Radiological and cosmetic improvement 2 years after brace weaning—a case report. *Pediatr Rehabil* 2003;6:195–9.
27. Kotwicki T, Kinel E, Stryla W, Szulc A. Discrepancy in clinical versus radiological parameters describing deformity due to brace treatment for moderate idiopathic scoliosis. *Scoliosis* 2007;2:18.
28. Duval-Beaupère G, Lamireau T. Scoliosis at less than 30 degrees. Properties of the evolutivity (risk of progression). *Spine (Phila Pa 1976)* 1985;10:421–4.
29. Bunnell WP. An objective criterion for scoliosis screening. *J Bone Joint Surg Am* 1984;66:1381–7.
30. Huang SC. Cut-off point of the Scoliometer in school scoliosis screening. *Spine (Phila Pa 1976)* 1997;22:1985–9.
31. Karachalios T, Sofianos J, Roidis N, Sapkas G, Korres D, Nikolopoulos K. Ten-year follow-up evaluation of a school screening program for scoliosis. Is the forward-bending test an accurate diagnostic criterion for the screening of scoliosis? *Spine (Phila Pa 1976)* 1999;24:2318–24.
32. Pruijs JE, Keessen W, van der Meer R, van Wieringen JC. School screening for scoliosis: the value of quantitative measurement. *Eur Spine J* 1995;4:226–30.
33. Pruijs JE, Keessen W, van der Meer R, van Wieringen JC, Hageman MA. School screening for scoliosis: methodologic considerations. Part 1: External measurements. *Spine (Phila Pa 1976)* 1992;17:431–6.
34. Weisz I, Jefferson RJ, Turner-Smith AR, Houghton GR, Harris JD. ISIS scanning: a useful assessment technique in the management of scoliosis. *Spine (Phila Pa 1976)* 1988;13:405–8.
35. Stokes IA, Moreland MS. Concordance of back surface asymmetry and spine shape in idiopathic scoliosis. *Spine (Phila Pa 1976)* 1989;14:73–8.
36. Aulisa AG, Guzzanti V, Galli M, Perisano C, Falciglia F, Aulisa L. Treatment of thoraco-lumbar curves in adolescent females affected by idiopathic scoliosis with a progressive action short brace (PASB): assessment of results according to the SRS committee on bracing and nonoperative management standardization criteria. *Scoliosis* 2009;4:21.
37. Lonstein JE, Carlson JM. The prediction of curve progression in untreated idiopathic scoliosis during growth. *J Bone Joint Surg Am* 1984;66:1061–71.
38. Rowe DE, Bernstein SM, Riddick MF, Adler F, Emans JB, Gardner-Bonneau D. A meta-analysis of the efficacy of non-operative treatments for idiopathic scoliosis. *J Bone Joint Surg Am* 1997;79:664–74.
39. Rigo M, Reiter Ch, Weiss HR. Effect of conservative management on the prevalence of surgery in patients with adolescent idiopathic scoliosis. *Pediatr Rehabil* 2003;6:209–14.
40. Weiss HR, Weiss G, Schaar HJ. Incidence of surgery in conservatively treated patients with scoliosis. *Pediatr Rehabil* 2003;6:111–8.
41. Maruyama T, Kitagawa T, Takeshita K, Mochizuki K, Nakamura K. Conservative treatment for adolescent idiopathic scoliosis: can it reduce the incidence of surgical treatment? *Pediatr Rehabil* 2003;6:215–9.
42. Danielsson AJ, Hasserijs R, Ohlin A, Nachemson AL. A prospective study of brace treatment versus observation alone in adolescent idiopathic scoliosis: a follow-up mean of 16 years after maturity. *Spine (Phila Pa 1976)* 2007;32:2198–207.
43. D'Amato CR, Griggs S, McCoy B. Nighttime Bracing with the Providence Brace in adolescent girls with idiopathic scoliosis. *Spine (Phila Pa 1976)* 2001;26:2006–12.
44. Goldbloom RB. *Screening for idiopathic adolescent scoliosis. In Canadian Task Force on the Periodic Health Examination.* Canadian guide to clinical preventive health care. Ottawa: Health Canada; 1994: 346–54.
45. Dolan LA, Weinstein SL. Surgical rates after observation and bracing for adolescent idiopathic scoliosis: an evidence-based review. *Spine (Phila Pa 1976)* 2007;32 (19 Suppl): S91–100.
46. Moen KY, Nachemson AL. Treatment of scoliosis: An Historical Perspective. *Spine (Phila Pa 1976)* 1999;24:2570–5.
47. Emans JB, Kaelin A, Bancel P, Hall JE, Miller ME. The Boston bracing system for idiopathic scoliosis. Follow-up results in 295 patients. *Spine (Phila Pa 1976)* 1986;11:792–801.
48. Lupporelli S, Padua R, Pitta L, Aulisa AG, De Santis V, Aulisa L. Correction of thoracolumbar and lumbar curves with a new short brace for idiopathic scoliosis. 1° Interdiscip. *World Congr On Spinal Surgery, Editors M Brock- W Schwarz-C Wille* 2000;487–91.
49. Aulisa L, Lupporelli S, Pola E, Aulisa AG, Mastantuoni G, Pitta L. Biomechanics of the conservative treatment in idiopathic scoliotic curves in surgical “grey-area”. *Stud Health Technol Inform* 2002;91:81–5.
50. Mehta M. Growth as a corrective force in the early treatment of progressive infantile scoliosis. *J Bone Joint Surg Br* 1987;9:1237–47.